

Automatic Biofibre® Hair Implant an Innovative Hair Restoration Technique for the Improvement of Quality Life

Dell Avanzato R^{1*}, Al Bzour B², Perez Rangel R³, Agrawal M⁴ and Serdev N⁵

¹Medical Department of Espace Chenot Health Wellness Spa-L'Albereta Relais & Chateaux, Italy

²Department of Dermatology-University Cluj-Napoca, Romania

³Professor of Anatomy and Surgical Technique at Xochicalco University, Mexico

⁴Department of Dermatology Fortis Hospital, Shalimar Bagh, India

⁵Honorary Professor at New Bulgarian University, Bulgaria

*Corresponding author: Roberto Dell' Avanzato, Medical Department of Espace Chenot Health Wellness Spa-L'Albereta Relais & Chateaux, Italy, Tel: +393316582739; E-mail: dellavanzato@hotmail.it

Received date: March 12, 2018; Accepted date: March 23, 2018; Published date: March 29, 2018

Copyright: © 2018 Avanzato RD, et al. This is an open-access article distributed under the terms of the Creative Commons Attribution License, which permits unrestricted use, distribution, and reproduction in any medium, provided the original author and source are credited.

Abstract

Background: The problem of alopecia affects both sexes at all ages with sometimes significant psychological sequelae. Along with androgenetic alopecia, there are forms of alopecia of various origin as traumatic, surgical, pharmacological and others. In 1993 the first biocompatible fibers (Biofibre®) were developed in Italy by Medicap company.

Aim: Automatic Biofibre® hair implant is a soft surgery technique which is performed under local anesthesia, that enables an immediate aesthetic result without pain, scars or hospitalization.

Methods: Biofibre® hair are similar to natural hair and they are available in 13 colors, that can be washed and dried with moderate heat, but cannot be bleached. The fibers are 15 cm long, until 45 cm. Besides straight fibers, there are also tight curl, soft curl and wave. Since the last years it is also available the MHD® hair variant that allows to use 3 hairs with the same graft. Automatic Biofibre® hair implant device allows to implant until 800 Biofibre® hair per hour reducing scalp trauma.

Results: This modern technique of hair restoration is indicated to treat diffuse hair loss or hair thinning, both for men and for women. Conditions for success are: suitable patient with healthy scalp, qualified physician, respect of implant protocol and after care application, correct identification and therapy of possible skin reactions.

Conclusions: Nowadays automatic Biofibre® hair implant is a valid surgical technique and can be also used alone or in combination with FUE to provide good final results.

Keywords: Hair implant; Hair surgery; Alopecia; Biofibre®; Hair loss; Cosmetic surgery

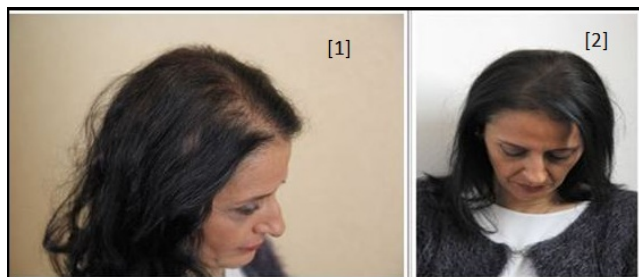Introduction

There is a strong social reason to justify patients who demand the implant of biocompatible artificial hair [1-6]. With exclusion of individual's dissatisfaction concerning his own image, such request often derive from the need to correct psychologic uneasiness or discomfort [7]. There are also patients whose aspect has been seriously modified by diseases whit no found solution. Post-surgical and post-traumatic defects are other indications. Female patients are particularly prone to experience the psychologic impact of hair loss [8] and thinning out (Figures 1 and 2). In all these cases, the aim of the implant of artificial hair is to restore self-esteem and so it is essential to warrant good results (Figures 3 and 4) [9-14].

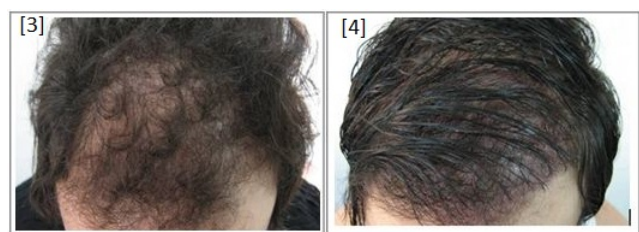
Moreover the system to anchor the fibers must allow to remove them, if necessary, without trauma or lasting scars (Figure 5) so the patient has an additional reason to desire implant benefits. Concerning the technique of hair implantation, it is the result of an experimental

research carried out in the last three decades. The artificial hair implant technique was developed during the 70-80 yrs in Japan, where it achieved a large success. Unfortunately, the rash application of this method by unqualified lay staffs (often hairdressers) working in no medical settings and without any protocol, with no patients screening and no follow up and also using unsuitable materials as polyester, modacrylic, polyacrylic and cut human hair, caused negative results. So the FDA suspended it in June 1983. However, in Europe the great interest in this procedure has stimulated intensive, pain staking scientific research.

In 1993 the first biocompatible fibers (Biofibre®) were developed in Italy by Medicap company. From 1993 onward clinical trials and histological studies were performed with encouraging results and leading to additional research on the biocompatible material field and medical protocol application. Consequently in 1996 artificial hair implant technique was listed among medical acts and included in the medical devices list. This was a fundamental step because since then only qualified Medical Doctors can perform this technique, only using suitable CE certified fibers. On the same year also the Australian TGA issued the same resolution.



Figures 1 and 2: Female hair thinning patient treated with Biofibre® implant.



Figures 3 and 4: Male patient treated with Biofibre® implant (immediately after the procedure).



Figure 5: Fiber removal without residues.

During the last 20 years, the improvement of the implant technique, deep studies concerning more suitable materials for implantation and a huge number of medical and scientific reports have clearly shown that good results can only be achieved in a qualified medical setting.

Materials and Methods

Various polymers already used for medical devices (polyesters, polypropylenes, polycarbonates, polymethylacrylate, fluoride resins etc.) have been tested for 30 yrs. and after a strict selection a particular fiber corresponding to all safety standards has been developed (Biofibre®; Medicap Italy). The suitable fiber has been obtained from a polymer already registered in the European Pharmacopoeia which is used as a non-absorbable suture thread. The pigments used to color this fiber meet all the purity and light fastness requirements specified in the Pharmacopoeia. They are incorporated in the polymer in the

liquid state, during extrusion, so that no colorant is shed into the human body. The special system by which this polymer is extruded allows production of a soft, flexible, thin fiber. These factors are very important during the postoperative period, as they give considerable advantages as a fast process of healing, no skin trauma and a natural aspect. Many laboratory tests, carried out both on the neutral polymer and the colored fibers have showed that the product is biocompatible and complies with the requirements of the European Pharmacopoeia. Implantation fibers are packaged on a special support which runs through their knots to keep them properly aligned. When the support is removed, the knob remains open, making connection easier. The fibers are sterilized in accordance with current norms. The innovative Biofibre® "reversible knot" anchoring system allows the fiber to be removed if necessary and the scalp returns to its natural condition without lasting scars. Besides allowing that cutaneous tissue hold the fiber securely in place this type of anchorage also satisfies the needs of the patient and the doctor concerning the risk/benefit ratio. Biofibre® hair is similar to natural hair and they are available in 13 colors, which can also be blended as appropriate to meet any aesthetic requirement. Their softness and their small diameter (0.08 mm) minimize the implant trauma and provide an immediate sensation of a thicker head of hair. They can be washed and dried with moderate heat, but cannot be bleached, dyed with aggressive products or permanently waved. The fibers are 15 cm long but this can be varied until 30 cm and 45 cm. Besides straight fibers, there are also three different degrees of wave or curl (tight curl, soft curl and wave) which withstand even frequent washing. Since the last years it is also available the MHD® hair variant that allows to use 3 hairs with the same graft. These fibers allow having one single knot implanted into the scalp. The distance between the knot and the 3 fibers is adjusted to allow the best skin healing as the 3 fibers don't have to enter in the same site but they are placed to the shaft of the fiber outside the scalp. This type of fiber was studied with the aim to supply more volume in those areas which are not clearly visible like the crown of the head. More visible areas like the front line will still be implanted with single Biofibre® hair. The other advantages of triple hair are: milder after care, bigger volume with less number of implants and quicker coverage of the scalp. The consequences are: higher yearly fall, especially on long fibers and worse aesthetic aspect than single fibers. In the last decades artificial hair implant was performed by hand instruments and lack of results was often linked to practice's mistakes. Recently an automatic implant device was developed. [2] Biofibre® automatic hair implant device in fact allows to implant until 800 Biofibre® hairs per hour reducing scalp trauma and implanting always at the right depth with an optimal clamp rate. This allows performing a correct implant even after several hours of work helping the job of the physician and increasing patient's satisfaction. The hole of introduction is much reduced and this allows a faster healing with reduced intervals among graft sessions with a big quantity of hairs. The patient returns to his/her own social life very rapidly after treatment with an immediate cosmetic result and a great psychologic benefit. The Biofibre® automatic implantation can be used alone or together with FUE. This enables to obtain an excellent result also in those patients who don't have a good donor area. The machine holds the body of the instrument which contains the needle. That's practical and functional, it has an end device which allows the length of the needle be adjusted in order to obtain the implant depth necessary for the thickness of the skin of the patient. The needle is stainless steel, 0.25 mm thin but very flexible and strong. The end of the needle is hooked to connect to the hair from the knot end. Needle replacement is quick and simple since the tip of the device has a guide. This hair implant technique is suitable to solve AGA, burns, trauma and many

other baldness cases. Good results are obtained if suitable patients are selected as healthy candidates who can undergo a medical follow-up. Patients affected by dermatosis or dermatitis of the scalp, metabolic impairments (diabetes or hypo-lipoproteinemia), autoimmune diseases, immune deficiencies, mental disorders, or whose scalp hygiene is not correct must be avoided. In the pre-operative phase, in addition to an accurate anamnesis and a general examination, the patient has to undergo routine clinical tests and, if necessary, even special products to make the scalp as suitable as possible for implant (for example by reducing sebum, dandruff etc.) A 100% implant fiber compatibility test is recommended at least one month before first implant session. The patient's hair is washed with a shampoo at physiological pH. After this treatment, the scalp is cleansed with a disinfectant solution as chlorhexidine and a local anesthetic is administered by a superficial injection (2% carbocaine or lidocaine with adrenalin 1:100,000) in order to cut off the implant area. After this, the skin is ready for the implant. To obtain the best results the Biofibre® hair has to be hooked and inserted in the scalp, holding it deep down with the needle until it has been removed from its sachet. The reversible knot must not close completely so that fibroblasts and connective fibers can grow around and through it, securing the artificial hair to the surrounding connective tissue. No more than 1000 hair per session should be implanted, placing them at 2 mm apart, positioning the knot in the galea at an angle of about 45° so that the hair lies in the same direction as the nearby natural hair. It's important not to implant 2 or more hair in the same hole and to wait at least 4-5 weeks among sessions to allow a right healing and to ensure a gradual change of image and self-perception. When the implant is complete, the scalp should be cleansed with a disinfectant lotion and then a wad of gauze soaked in saline solution plus antibiotic should be applied. Also a local antibiotic can be injected. An ice pack for at least 5-10 mins should be applied. An antibiotic systemic therapy is provided for 1 week and a twice per day use of local antiseptic spray is recommended for the first 2 weeks then daily for other 2 weeks. The first shampoo will be performed 3 D after implant. We can wash the hair with almost cold water and use a medical shampoo as ketoconazole, drying with lukewarm air. Post-operative care is very important for the success of the implantation. The patient has to be properly informed about the most suitable products for use and must avoid substances which may cause deterioration of the implanted hair (aggressive dyes, lacquers, gels, acids, permanent waves, etc). He must wash his hair frequently with the recommended shampoo. To prevent sebum accumulation he has to gently massage the scalp with a Biofibre® soft toothbrush every 2 weeks during shower and avoid traction during combing. The implanted fibers and the scalp must always be treated gently. The implanted hair must be dried with lukewarm air, or left to dry naturally. Medical checks have to be carried out regularly in average every 2-3 months for the first year and could also include the removal of any sebum plugs, responsible for irritation as well as the loss of implanted hairs. Sebum plugs when present have to be removed using pincers or a black head remover spatula, applying firm pressure to eliminate the sebum deposited inside the new follicle. Afterwards it's necessary to disinfect and cleanse the scalp thoroughly. Sebolytics and keratolytics products are suggested to reduce sebum accumulation as well as the use of Biofibre® soft toothbrush. Infections may occur due to poor disinfection during implantation, unsuitable local conditions, inadequate scalp hygiene, and lack of after-care, sebum plug accumulation or failure to carry out postoperative follow up. Infections are mostly treated and solved by antibiotic therapy. If infection recurs, fibers removal is suggested. Inflammatory complications are due to the use of irritating or aggressive substances

(acids, permanent waves, dyes, lotions, lacquers, gels, etc). which become trapped in the newly formed follicle and may lead to sensitization. Avoiding or reducing this product application and using appropriate substances leads to resolve the problem. In case of infection and inflammation, a combination between antibiotics and steroid is suggested according to each patient. As infection or inflammation, other causes of grafted hair loss are the following: in case the knot comes undone, if the fiber has not been implanted in the galea capitis, if more than one hair is implanted in one hole, if plugs of sebum are formed and if the fiber is pulled up into the adipose layer.

Results

A clinical study was performed by Serdev et al. [15] in 133 patients (98 males and 35 females). All of them had healthy scalp, good hygiene and good general health. The quantity of implanted fibers was up to 6000 and the majority of patients were in 30-60 yrs range and III/IV Hamilton scale. Yearly fiber loss was less than 10% in 91.4% of cases. Patients with no complications were 90.3%. The 5.9% of patients showed mild infection and 3.8% presented inflammatory complication. These complications were resolved in the majority of cases with a patient satisfaction of 96.2%. The 2.1% of the patients received fibers removal. Another study performed by Santiago et al. [16] demonstrates the validity of the procedure to treat scalp scars. The study involved 44 patients with 54 scalp scars. Male patients were 36, female patients were 8. Age range was 17-64 yrs. 90.74% of patients had no complications while 7.41% of them presented mild problems solved with appropriate therapy. Only 1.85% underwent fibers removal. The average yearly loss of fibers was around 20%. The graft reported on this study was performed by manual implant and that is the cause of higher loss since the scar tissue is tougher than normal one. This inconvenient is now overcome by the use of automatic machine. Fanti et al. [17] reported that histological modifications associated to the implant of artificial fibers depend on the anatomical structures which the fibers encounter. After implanting of artificial hair acute inflammation occurs due to the reaction to the foreign body; clinically this is evident because of a through slight redness and swelling which disappear after 4-5 D. After about one month, artificial hair is surrounded by hyperplastic epidermis in both the papillary dermis and in the upper part of the reticular dermis. This proliferation of the epidermis is known as the pseudo-infundibulum. Inside it, the fibers are surrounded by a keratin layer. The pseudo-infundibula reach down to the top of the reticular dermis, where they gradually become thinner and disappear. Below this, the fibers are bare, in direct contact with the collagen bands of the medium and deep reticular dermis. Here the fibers are surrounded by a small amount of chronic granulomatous infiltrate. There is no track of colorant in the surrounding cutaneous tissue. So Fanti et al. [17] shows that inflammation is histologically negligible and does not give rise to clinically evident inflammation.

Discussion and Conclusions

The aim of this paper is to show that nowadays automatic implantation of biocompatible artificial hair (Biofibre®) into the human scalp is a valid surgical technique to cover areas which are thinning and/or bald as a result of androgenetic alopecia and to treat post-surgical or post-traumatic defects. This technique can be also used alone or in combination with FUE to provide good final results. Automatic Biofibre® hair implant can be also considered a worthwhile solution for female baldness or hair thinning. It is also performed experimentally to treat total alopecia. The strong social motivation and

the cosmetic result expected by the patient are further justified by the safety of this kind of "reversible" implantation, since if necessary the fibers can be completely removed without trauma or lasting scars. We also wish to underline the excellent results obtained when artificial hair is implanted in accordance with a strict protocol.

We can therefore affirm that the implant of artificial hair is an easy and soft surgical technique for baldness treatment which gives immediate benefits in terms of cosmetic results; these are in fact very good in more than 90% of cases. So the vast majority of patients is very satisfied and benefits of an excellent psychological impact on his quality of life.

References

1. Williamson D, Gonzales M, Finlay A (2001) The Effect of Hair Loss on Quality of Life. *J EADV* 15: 137-139.
2. Dell' Avanzato R (2017) Automatic artificial hair implant 38th National Congress of the Italian Society of Aesthetic Medicine (SIME). Rome, Italy, May 12-14.
3. Lotti T Aesthetic Disability (2017) 38th National Congress of the Italian Society of Aesthetic Medicine (SIME). May 12-14.
4. Franca K, Chacon A, Ledon J, Savas J, Nouri K (2013) Psychological Impact of Scars. Nova Science Publishers.
5. Van Der Donk J, Hunfeld JA, Passchier J, Knecht-Junk KJ, Nieboer C (1994) Quality of Life and maladjustment associated with hair loss in women with alopecia androgenetica. *Soc Sci Med* 38: 159-163.
6. Ramos O, Tchernev G, Chokoeva AA, Wollina U, Maximov GK, et al. (2016) Biofibre® Hair Implant-Impact on the Quality of Life. *J Biol Regul Homeost Agents* 30: 21-25.
7. Alfani S, Antinone V, Mozzetta A, Pietro C, Mazzanti C, et al. (2012) Psychological Status of Patients with Alopecia Areata. *Acta Dermatol Venereologica* 92: 304-306.
8. Cash TF, Price VH, Savin RC (1993) Psychological Effects of Androgenetic Alopecia on Women: Comparison with Balding Men and with Control Female Subjects. *J Am Acad Dermatol* 29: 568-575.
9. Di Gregorio VR, Rauscher G (1981) Experience with the complications of synthetic hair implantation. *Plast Reconstr Surg* 68: 498-504.
10. Schwartz RS, Downham TF (1980) Dangers of synthetic fiber implantation for male pattern baldness. *Cutis* 25: 491-492.
11. Tchernev G, Sheta M, Rahoui M, Chokoeva A.A, Wollina U, et al. (2016) Biofibre® Hair Implant: What is New, What is True? *JBRHA* 30: 27-34.
12. Palmieri B, Griselli G, D'Ugo A, Palmieri G, Salti G (2000) Evaluation of polyamide synthetic hair. A long-term clinical study, *Panminerva Med* 42: 49-53.
13. Santiago M, Perez Rangel R, D'ugo A, Griselli G, Igitian G, et al. (2007) Artificial Hair Fiber Restoration in the Treatment of Scalp Scars. *Dermatol Surg* 33: 35-44.
14. Franca K (2017) Oxford Clinical Handbook: Current and Emerging Therapies in Hair Transplantation and Hair Implants. *GHC Communications*
15. Serdev N, D Erme AM, Hercogova J, Zarrab Z, Chokoeva AA, et al. (2015) Polyamide hair implant (Biofibre®): evaluation of efficacy and safety in a group of 133 patients. *JBRHA* 29: 103-109.
16. Santiago M, Perez Rangel R, D'ugo A, Griselli G, Igitian G, et al. (2007) Artificial Hair Fiber Restoration in the Treatment of Scalp Scars. *Dermatol Surg* 33: 35-44.
17. <http://www.biofibre.com/en/results/clinical-trials/>